

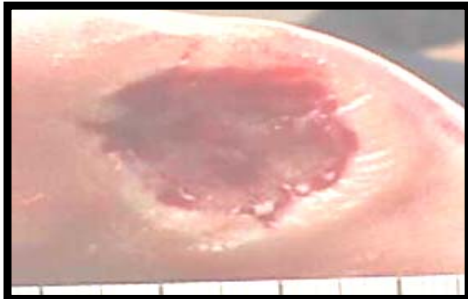


**EXCELLARATE Phase 1/2 Product Candidate  
(Selected Case Studies Provided by TRC)**

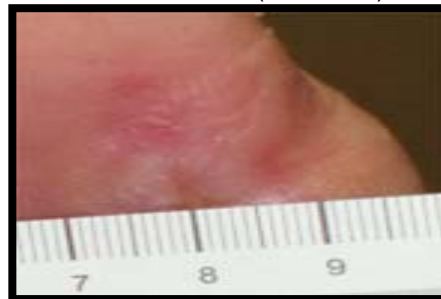Excellerate, a DNA-based collagen matrix gel for topical treatment formulated with an adenovector delivery carrier that encodes for human Platelet-Derived Growth Factor-B (PDGF-B), has been studied in an initial 15-patient, multi-center Phase 1/2 clinical trial that evaluated preliminary safety and included an assessment of healing. Based on the data from TRC's study, Excellerate appeared to be safe and well tolerated in the 12 patients that completed the treatment protocol and follow-up, with over 80% of patients showing complete wound closure by 14 weeks.

**Patient #01:** This patient is a 49-year old male with a medical history of hypertension, type II diabetes mellitus, inability to perceive 10 gm monofilament device in all quadrants, bilateral feet and lower extremities, right plantar great toe ulcer, and lower extremity edema. Ulcer-related treatment history included sharp debridement, accuzyme (enzymatic debrider) and KCI wound vacuum device. The patient presented with a Grade 1, plantar ulcer measuring 2.5 cm x 2.3 cm on the right foot, great toe that had been unsuccessfully treated for three years prior to enrolling in the Excellerate Phase 1/2 clinical study. This patient was scheduled for amputation of his great toe due to failure of healing. He was treated with 4 applications of the mid-dose Excellerate given on a weekly basis. The patient's ulcer healed 8 weeks after the fourth application of the drug.

Before Treatment

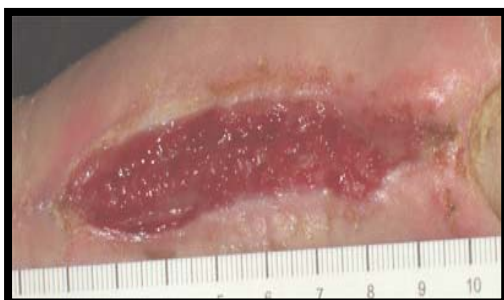

After Treatment (12 weeks)

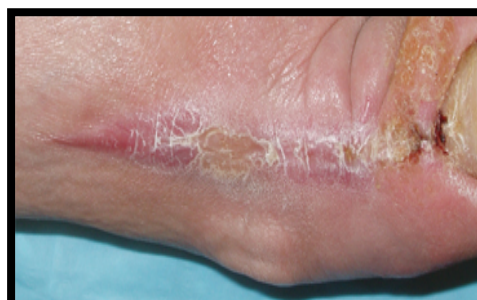

**Patient #02:** This patient is a 46-year old male with a medical history of peripheral neuropathy, right foot dorsal ulcer, and type II diabetes mellitus. Prior ulcer-related surgical history included incision and debridement. Ulcer-related treatment history includes Neosporin, wet to dry dressings (standard of care), and accuzyme (enzymatic debrider). The patient presented with a Grade 1, dorsal ulcer measuring 6.0 cm x 1.2 cm on the right foot and had been unsuccessfully treated for approximately 6 months before enrolling in the Excellerate Phase 1/2 clinical study. He was treated with 4 applications of Excellerate given on a weekly basis. The patient's ulcer healed 8 weeks after the fourth application of the drug.

Before Treatment

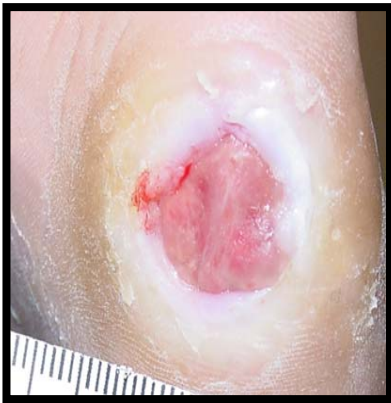

After Treatment (11 weeks)

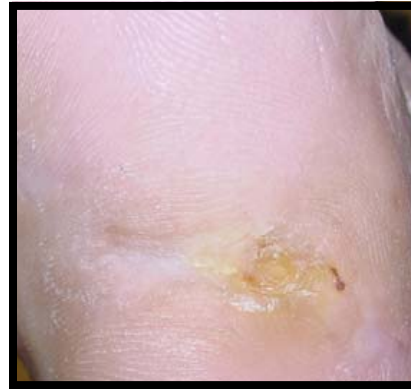

**Patient #03:** This subject is a 58-year old male with a medical history of bilateral foot neuropathy and right hand neuropathy, hypertension, coronary artery disease, atrial fibrillation, sick sinus syndrome, and peripheral vascular disease, claudication R>L, diabetes mellitus type II, hyperlipidemia, azotemia, and fifth metatarsal left foot plantar medial ulcer. Prior ulcer-related surgical history included amputation left fourth toe. Ulcer-related treatment history includes acticoat, gauzes, and ointment and clindamycin. This patient presented with a Grade 1, plantar medial ulcer measuring 1.2 cm x 1.2 cm on the left foot and had been unsuccessfully treated for approximately 6 months before enrolling in the Excellerate Phase 1/2 clinical study. He was treated with a single application of Excellerate. The patient's ulcer healed 13 weeks after application of the drug.

Before Treatment



After Treatment (13 weeks)



## Gene Activated Matrix (GAM) Technology

- **PDGF adenovector**

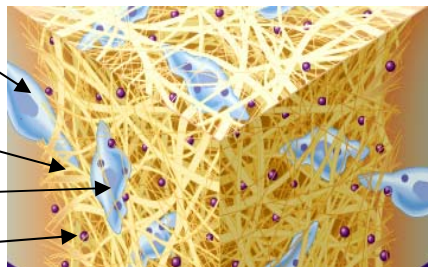
- Can transfect patient cells
- Infected cells produce high levels of PDGF for 7-10 days
- Negatively charged

Cell migrating into wound

Collagen matrix

Transfected cell

PDGF Adenovector



- **Collagen**

- Three dimensional space
- Gel Consistency
- Positively charged

- Collagen matrix traps PDGF adenovector in wound and attracts cells



- PDGF adenovector transfects patient repair cells and leads to PDGF production.



- PDGF production stimulates wound healing



- High amounts of PDGF produced for sustained period in wound with a formulation that is easy to apply

